

The morphology of extracted testicular sperm correlates with fertilization but not pregnancy rates

Jonathan D. Schiff*†, Martha Luna†, Jason Barritt†, Marlena Duket†, Alan Coppersman†‡ and Natan Bar-Chama*†‡

Departments of *Urology and †Obstetrics and Gynecology, Mount Sinai School of Medicine, and ‡Reproductive Medicine Associates of New York, New York, NY, USA

Accepted for publication 1 June 2007

Study Type – Prognosis (outcomes research)
Level of Evidence 2c

OBJECTIVE

To investigate sperm morphology on the day of fresh testicular sperm extraction (TESE) with intracytoplasmic sperm injection (ICSI), and its effect on fertilization and pregnancy rates, as TESE in conjunction with ICSI results in high fertilization and pregnancy rates in most patients, but to our knowledge only one small study has assessed the morphology of retrieved sperm and found no correlation with the success of fertilization.

PATIENTS AND METHODS

In a retrospective database analysis in a large academic centre, 68 men had 75 cycles of TESE combined with ICSI from January 2004 until April 2006. Sperm obtained by TESE was morphologically analysed at high ($\times 400$ – 600) magnification and used for ICSI on the day of

tissue retrieval. Sperm were classified as being either normal, having an amorphous head, having a mid-piece defect or having multiple defects. The calculated percentage of abnormal sperm injected was compared with the normal fertilization rate using Pearson's correlation coefficient, and pregnancy rates between groups were compared using chi-square analysis.

RESULTS

Fifteen cycles had all morphologically normal sperm; 21 cycles had 50–99% normal forms and 39 cycles had <50% normal sperm. There was a highly significant correlation between the percentage of normal sperm used for ICSI and fertilization rates ($P = 0.007$). Overall, 43 clinical pregnancies resulted in this series, i.e. three among the group with all normal sperm injected, 12 in the group with 50–99% normal sperm and 28 in the group with <50% normal forms. There were also 11 pregnancies in cycles that used no normal forms. Pregnancy

rates did not differ significantly among the groups ($P = 0.08$).

CONCLUSIONS

TESE with ICSI frequently results in successful pregnancy; normal morphology was highly and significantly associated with successful fertilization, but importantly there were still 10 clinical pregnancies in cycles where only abnormal sperm were used. Sperm morphology after TESE should be assessed at the time of the procedure, and whenever possible, morphologically normal sperm chosen for injection. However, it is reassuring that acceptable fertilization and pregnancy rates are still achievable in cases with no morphologically normal sperm available.

KEYWORDS

testicular sperm extraction, microsurgery, results, IVF/ ICSI, male infertility, sperm morphology

INTRODUCTION

Sperm function is critical for the process of normal fertilization in the female reproductive tract. The sperm must traverse the vagina, cervix, uterus and then most often fertilizes the ovum in the oviduct. Sperm morphology is thought to be closely related to sperm function, and, as reported by Kruger *et al.* [1], sperm morphology is correlated with the success of conventional *in-vitro* fertilization (IVF).

Sperm retrieved directly from the testis never attain full normal function, as maturation occurs in the epididymis. Testicular retrieval can successfully obtain sperm in even the most difficult cases up to 60–70% of the time [2]. Even though this sperm is not mature and

often morphologically abnormal, excellent fertilization and pregnancy rates can be achieved with testicular sperm using intracytoplasmic sperm injection (ICSI) [3,4].

As ICSI bypasses the normal process of sperm penetration and fertilization, little attention has been paid to the effect of testicular sperm morphology on fertilization and pregnancy rates for IVF with ICSI. Yavetz *et al.* [5] examined the sperm head dimension, acrosome and mid-piece irregularity to determine if morphology affected the fertilization rate in 27 men; they found no relationship in that small series.

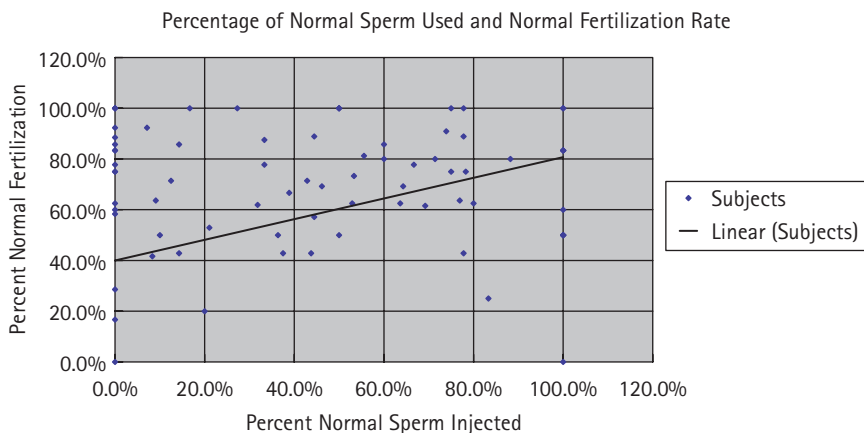
We examined whether the morphology of freshly retrieved testicular sperm affects

fertilization and pregnancy rates in men undergoing IVF with ICSI using testicular extracted sperm (TESE).

PATIENTS AND METHODS

We retrospectively investigated our IVF database and found 75 consecutive cases (68 patients) of TESE combined with ICSI. Men were diagnosed as azoospermic if they had two or more consecutive semen analyses showing no spermatozoa after high-speed centrifugation at 3000 *g*. Eleven men (who participated in 13 ICSI cycles) were defined as having unobstructive azoospermia (UOA) by histological and hormonal variables and 57 (who participated in 62 ICSI cycles) were considered to have obstructive azoospermia

FIG. 1. The percentage of normal sperm used and the normal fertilization rate.



Variable	Group, % normal sperm			TABLE 1 The mean number of eggs injected, the mean number of normal sperm used, fertilization and pregnancy rates
	0–50	51–99	100	
Mean:	39	21	15	
maternal age, years	36.6	37.1	37.4	
paternal age, years	41.6	38.5	42.2	
N eggs injected	11.1	11.8	5.5	
Mean (%) normal sperm for ICSI	1.1 (15)	7.96 (67)	5.5 (100)	
% normal fertilization	67.2	75.5	64.5	
Pregnancies/total, n/N (%)	28/39 (72)	12/21 (57)	3/15	

(OA). Two men with UOA and five with OA had multiple retrievals and ICSI cycles.

For patients with presumed OA (normal FSH and LH levels, normal testosterone, or absent vasa or a history of vasectomy or inguinal surgery), percutaneous TESE was used. Briefly, under local anaesthesia with or without sedation, a small stab incision was made in the scrotum through the dartos muscle. An 18 G biopsy gun (Bard Urological, Covington, GA, USA) was used to take two to three cores from the testis until sperm with 'twitching' motility were found. Manual pressure was then applied for 10 min and the incision closed with interrupted 3–0 chromic sutures.

In those patients with either hormonal abnormalities (high FSH) or no history of inguinal surgery, microsurgical TESE was used. Briefly, under general anaesthesia, an incision was made in the hemiscrotum of the larger testis; the testis was then delivered and the tunica albuginea incised to reveal the seminiferous tubules. The tubules were then examined under an operating microscope

(Carl Zeiss, Inc. Dublin, Eire) and the tubules that appeared plump were extracted first, placed in human tubal fluid, and dissected under a microscope by an experienced embryologist. The aspirate of the fluid was then examined under a working microscope ($\times 400$ – 600) and any sperm found were gathered using a micromanipulation pipette. ICSI was carried out by an experienced embryologist at ≈ 41 h after stimulation by hCG, with analysis for normal fertilization (two pronuclei) being assessed at 16–18 h after ICSI.

Sperm morphology was analysed by experienced embryologists (M.D. and J.B.) at $\times 400$ – 600 ; sperm were classified as being either normal, having an amorphous head, having a mid-piece defect or having multiple defects. Because all sperm were analysed on the day of ICSI, no staining was used and the sperm that were used for ICSI were classified by the above criteria. The embryologist grading the spermatozoa was unaware of the presumptive diagnosis of the patient as either OA or UOA. Men were segregated

into whether they had <50% normal sperm injected, 50–99% normal or 100% normal.

We calculated the percentage of normal and abnormal sperm injected during ICSI and compared it with the fertilization rate for couples using only normal sperm, using Pearson's correlation coefficient. Group means for the number of normal or abnormal sperm used were compared with an unpaired Student's *t*-test; fertilization and pregnancy rates between groups were compared using chi-squared analysis. In all, tests $P < 0.05$ was considered significant. We compared patients classified as having OA to those UOA.

RESULTS

Fifteen cycles (20%) had completely normal sperm used for ICSI, 21 (28%) had 50–99% normal forms and 39 (52%) had <50% normal sperm used in ICSI. There was a strongly significant correlation between the percentage of normal sperm used for ICSI and fertilization rates ($P = 0.007$; Fig. 1). The mean number of eggs injected, the mean number of normal sperm used, fertilization and pregnancy rates are listed in Table 1.

Overall, 43 clinical pregnancies (57%) resulted from this series; three of the 15 with all normal sperm injected, 12 of 21 (57%) in the group with 50–99% normal sperm injected and 28 (72%) in the group with <50% normal forms injected. Eleven (36%) of the pregnancies achieved in the latter group occurred in cycles in which no normal forms were used. Pregnancy rates did not differ significantly between groups ($P = 0.08$).

We compared cycles where no normal sperm were used with cycles where any normal sperm were used for IVF with ICSI; 17 cycles were used with no normal sperm injected, with a 70% normal fertilization rate and a 65% pregnancy rate. This compared to a 70% normal fertilization rate and a 55% pregnancy rate in couples where any normal sperm were injected ($P = 0.49$).

We compared men who had UOA and required microdissection TESE to those men with OA who had percutaneous TESE. The mean age of men with UOA was 39.8 years and their partners' mean age was 37 years. In the group with OA the mean age was 41 years and the mean partner age was 36.9 years ($P = 0.76$ for men and 0.96 for women).

Of the 11 men who had 13 ICSI cycles in the UOA group, pregnancies were achieved in seven. A median of four normal sperm per cycle was injected into a median of 10 ova, with a 56% normal fertilization rate. The mean percentage of normal sperm used for this group was 29%. Among men with OA, 35 pregnancies were achieved in 62 cycles (57%, $P=0.65$ vs UOA group). The median number of ova injected was 11 with a median of four normal sperm per cycle; the mean percentage of normal sperm used was 48% ($P=0.06$). The percentage normal fertilization was 72% for the group ($P=0.13$). None of these differences between the groups was significant.

There was a weak negative correlation between paternal age and number of normal sperm found for ICSI (Pearson $r = -0.28$); there was no correlation between paternal age and normal fertilization percentage (Pearson's $r = -0.05$).

DISCUSSION

TESE with ICSI frequently results in successful pregnancies. Since the description of ICSI in 1992 by Palermo *et al.* [6] the correlation of sperm morphology with IVF outcomes, as described by Kruger *et al.* [1] has been questioned. However, many studies have examined the use of ejaculated sperm to investigate the correlation between sperm morphology and ICSI outcomes; none has found a correlation between morphology and fertilization rates [7–14].

More recently, Yavetz *et al.* [5] investigated the correlation between morphology of testicular sperm and ICSI fertilization outcomes; they studied 27 men, seven with OA and 20 with UOA, and counted 200 sperm cells, according to WHO (1992) guidelines and only evaluated mature sperm with a full-grown tail. Sperm were analysed according to head dimensions, acrosome and mid-piece irregularities using the strict criteria of Menkveld *et al.* [15]. They found no significant correlation between normal morphology and age or testis volume, and nor was there a difference in fertilization rate according to sperm morphology.

The present study differed from this important work in several respects. We analysed the actual sperm that were used for ICSI instead of a sample of sperm cells from

each patient. We did not stain the sperm using any dyes or fixatives, as these were the sperm used for ICSI. An experienced embryologist analysed all the sperm and reported their morphology. Normal morphology was significantly associated with successful fertilization. Women whose partners had more normal sperm retrieved and used for ICSI had more embryos with normal fertilization. However, this increase in normal fertilization rates did not translate into higher pregnancy rates. Importantly there were still 11 clinical pregnancies in cycles where only abnormal sperm were used for ICSI. Indeed, while there was no significant difference among the groups, there was a trend towards greater pregnancy rates in the group with the fewest normal sperm used. We also compared results between groups where no normal sperm were used and where any normal sperm were used; the fertilization rates and pregnancy rates did not differ.

Pregnancy rates were not significantly different between groups but there was a trend, with better rates among couples where lower percentages of normal forms were used. This is a surprising finding, but given the ability of ICSI to bypass the normal process of fertilization, using any sperm with intact DNA allows a chance for fertilization. The mean number of eggs injected was 11 or 12 per group with <50% or 50–99% of normal sperm used, but only five in the group where all normal forms were used. Clearly the use of fewer eggs had an important effect on pregnancy outcomes in this instance.

The cause of azoospermia also did not affect the ultimate fertilization or pregnancy rates. While men with OA had a higher normal fertilization rate (72% vs 56%), this difference was not significant ($P=0.11$). The mean percentage of normal sperm used was higher for the men with OA (48%) than with UOA (29%). This difference was not statistically different ($P=0.06$), but this might be a result of lack of statistical power to detect this difference. Importantly, the pregnancy rates between the groups with UOA (54%) and OA (57%) were equivalent ($P=0.65$).

Sperm morphology after TESE should be assessed at the time of the procedure, and when possible morphologically normal sperm should be used for injection. However, excellent fertilization and pregnancy rates are still achievable in cases with no morphologically normal sperm available. At

the time of sperm retrieval for ICSI, any sperm that are isolated can be used for injection, with a reasonable expectation of success.

ACKNOWLEDGEMENTS

Supported by the Pfizer/AUA fellowship in sexual medicine 2005–2006.

CONFLICT OF INTEREST

None declared.

REFERENCES

- 1 Kruger TF, Acosta AA, Simmons KF, Swanson RJ, Matta JF, Oehninger S. Predictive value of abnormal sperm morphology in *in vitro* fertilization. *Fertil and Steril* 1988; **49**: 112–7
- 2 Schiff JD, Palermo GD, Veeck LL, Goldstein M, Rosenwaks Z, Schlegel PN. Success of testicular sperm injection and intracytoplasmic sperm injection in men with Klinefelter syndrome. *J Clin Endocrinol Metab* 2005; **90**: 6263–7
- 3 Silber SJ, Van Steirteghem AC, Nagy Z, Liu J, Tournaye H, Devroey P. Normal pregnancies resulting from testicular sperm extraction and intracytoplasmic sperm injection for azoospermia due to maturation arrest. *Fertil Steril* 1996; **66**: 110–7
- 4 Tarlatzis BC, Bili H. Survey on intracytoplasmic sperm injection: report from the ESHRE ICSI Task Force. *Hum Reprod* 1998; **13** (Suppl. 1): 165–77
- 5 Yavetz H, Yogev L, Kleiman S *et al.* Morphology of testicular spermatozoa obtained by testicular sperm extraction in obstructive and nonobstructive azoospermic men and its relation to fertilization success in the *in vitro* fertilization – intracytoplasmic sperm injection system. *J Androl* 2001; **22**: 376–81
- 6 Palermo G, Joris H, Devroy P, Van Steirteghem AC. Pregnancies after ICSI of a single spermatozoon into the oocyte. *Lancet* 1992; **340**: 17–8
- 7 Kupker W, al-Hasani S, Schulze W. Morphology in intracytoplasmic sperm injection: preliminary results. *J Assist Reprod Genet* 1995; **12**: 620–6
- 8 Nagy ZP, Liu J, Joris H *et al.* The result of intracytoplasmic sperm injection is not

- related to any of the three basic sperm parameters. *Hum Reprod* 1995; **10**: 1123–9
- 9 **Hammadeh ME, al-Hasani S, Stieber M *et al.*** The effect of chromatin condensation (aniline blue staining) and morphology (strict criteria) of human spermatozoa on fertilization, cleavage and pregnancy rates in an intracytoplasmic sperm injection programme. *Hum Reprod* 1996; **11**: 2468–71
- 10 **Svalander P, Jakobsson AH, Forsberg AS.** The outcome of intra-cytoplasmic sperm injection is unrelated to strict criteria sperm morphology. *Hum Reprod* 1996; **11**: 1029–2
- 11 **Lundin K, Soderlund B, Hamberger L.** The relationship between sperm morphology and rates of fertilization, pregnancy and spontaneous abortion in an in-vitro fertilization/intracytoplasmic sperm injection program. 1997;12: 2676–81
- 12 **Novero V, Camus M, Tournaye H *et al.*** Relationship between serum follicle stimulating hormone in the male and standard sperm parameters, and the results of intracytoplasmic sperm injection. *Hum Reprod* 1997; **12**: 59–63
- 13 **Tasdemir I, Tasdemir M, Tavukcuoglu S, Kahraman S, Biberoglu K.** Effect of abnormal sperm head morphology on the outcome of intracytoplasmic sperm injection in humans. *Hum Reprod* 1997; **12**: 1214–7
- 14 **Sukcharoen N, Sithipravej T, Promviengchai S.** Sperm morphology evaluated by computer (IVOS) cannot predict fertilization rate in vitro after intra-cytoplasmic sperm injection. *Fertil Steril* 1998; **69**: 564–8
- 15 **Menkveld R, Stander FSH, Kotze TJ, Kruger TF, VanZyl JA.** The evaluation of morphological characteristics of human spermatozoa according to stricter criteria. *Hum Reprod* 1990; **5**: 586–92

Correspondence: Jonathan D. Schiff, 635 Madison Avenue, New York, NY, 10021, USA
e-mail: Drschiiff@gmail.com

Abbreviations: IVF, *in-vitro* fertilization; ICSI, intracytoplasmic sperm injection; TESE, testicular sperm extraction; (U)OA, (un)obstructive azoospermia.

EDITORIAL COMMENT

These authors investigated the effect of sperm morphology on fertilization and pregnancy rates in an ICSI-TESE setting and found normal fertilization and pregnancy rates in cases with no morphologically normal sperm available. When reading this study two

questions came to mind. How can this remarkable fertilizing potential of abnormal spermatozoa be explained, and do these findings permit a more liberal injection regimen in the laboratory? In other words, is it safe for the offspring to inject any testicular sperm irrespective of morphology? To address the first question, even though sperm samples were graded into a category with no morphologically normal sperm, it is still not absolutely certain if a morphologically normal or abnormal spermatozoon was injected in any given single oocyte. Even when an experienced embryologist judges a sample to be all morphologically abnormal, a normal sperm could have been present and injected. To address the effect of sperm morphology on pregnancy rates in ICSI-TESE in a scientifically valid way, the fate of each normal or abnormal spermatozoon from injection to pregnancy should have been followed in a prospective study. The question of whether the results of this study permit a more liberal injection regimen in the clinical TESE-ICSI setting requires a study that goes beyond pregnancy rates and involves neonatal and early childhood data.

Eric J.H. Meuleman,

*Professor of Andrological Urology,
Consultant Urologist/Sexologist,
Free University Medical Centre, Amsterdam,
the Netherlands*